

Advanced Dental care

Last month, XL Equine vets discussed the importance of basic dentistry, but what happens if they find a problem?

All horses should receive routine dental care at least once a year to prevent sharp enamel points forming, which can cause trauma to the soft tissues of the mouth (see *May Horse&Rider*). As part of this care, your veterinary surgeon will carry out a thorough oral examination, which can aid early identification of dental problems that may require further advanced dental care. Here are some of the more common mouth issues vets may come across...



Abscesses can cause discharge from one nostril

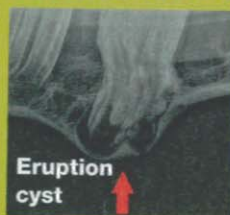Tooth root abscesses

These most commonly affect younger horses of four to seven years old. There are many causes of abscesses, including trauma, fracture, or infection in or around the tooth. Swelling and a discharging tract are seen if a lower jaw molar is affected. Upper jaw molar root abscesses may cause swelling and/or smelly nasal discharge from one nostril.

Diagnosis requires sedation and X-rays to identify which tooth is affected. Sometimes, in the early stages, there may be little in the way of changes on the X-rays and further diagnostic procedures may be necessary.

Treatment requires a long course of antibiotics and, if appropriate, dental work to correct the underlying problem. Where the sinus is infected with upper jaw abscesses, flushing is carried out using an in-dwelling catheter. Cases that do not respond to initial treatment will require tooth extraction.

Cheek tooth impaction



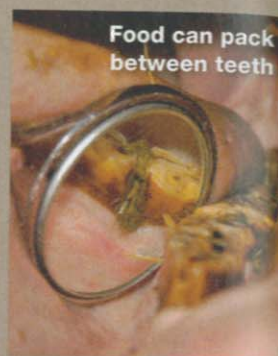
Eruption cyst

Caused by excessive compression between the cheek teeth, impaction most commonly affects the second and third cheek tooth. Mild cases develop an eruption cyst – seen as a non-painful lump on the lower or upper jaw at three to four years of age, which usually resolves with time.

Severe cases have a large, hot, painful swelling on the jaw that can develop into a tooth root abscess.

Gaps – diastema – and periodontal disease

A diastema is a gap between the molar teeth into which food packs, causing painful gum infection known as periodontal disease. There are many causes, including overcrowding, poor tooth compression and displaced teeth.



Food can pack between teeth

Signs seen include bad breath (halitosis), quidding (dropping food), weight loss and pouching of food in the cheeks. Affected horses are also more likely to develop choke and impaction colic due to poor chewing of fibre. Untreated periodontal disease can lead to complications such as infection of the tooth root, surrounding bones and sinuses.

Diagnosis is made on thorough examination under heavy sedation as these areas are very painful. This involves clearing out all the food material to assess the depth of the gum disease. Treatment involves flushing out all the food material, then antibiotic gel and impression material can be used to fill the defect and protect the area from food to allow gum healing. This procedure often needs to be repeated several times.

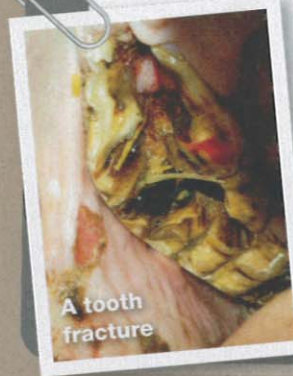The diastema may need to be widened using mechanical burrs to allow food to move freely out of the space. This procedure requires extreme care to prevent permanent damage to the sensitive structures of the teeth and must only be carried out by a veterinary surgeon.

Occasionally, treatment requires tooth extraction in the cases of severely displaced or overcrowded teeth. A diet of short-chopped grass and high-fibre nuts can help to reduce the food packing.

Tooth fractures

Diagnosis of tooth fractures requires sedation, thorough examination and sometimes X-rays. They are caused by trauma, displacements or dental decay.

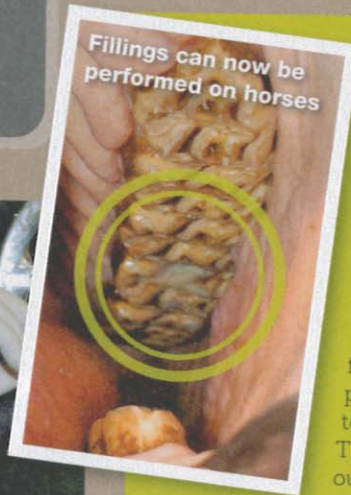Badly fractured teeth may require extraction, but less severe cases are managed by removal of loose fragments, tetanus protection and antibiotic treatment. The opposing tooth is reduced to prevent pressure on the fractured tooth and, if necessary, the damaged tooth can be stabilised using wire bridges. A soaked concentrate diet in the short term may be necessary to allow the tooth to rest and heal.



A tooth fracture

Dental caries

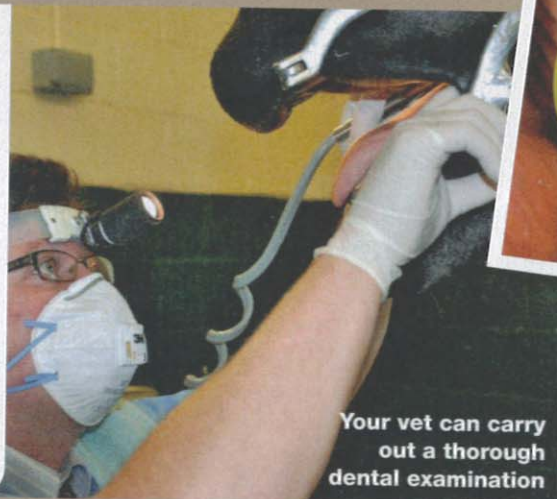
Dental caries is dental decay in the tooth, and it can weaken the tooth and lead to fractures and tooth root infections. Caries can only be identified on a detailed oral examination. Dental fillings can now be performed on these defects to halt the decay process. The decayed tooth is drilled out, flushed and filled using specialist equipment.



Fillings can now be performed on horses

FOR MORE INFORMATION

XL Equine is a group of 35 independently owned equine veterinary practices who work together. To find out more about equine dentistry, and other treatments and conditions, visit xlequine.co.uk



Your vet can carry out a thorough dental examination

★★★ Rate this feature

Go to tinyurl.com/RateJune for a chance to win a Mountain Horse Crew jacket (see p9).