

Equine matters

WINTER 2018

Nasal discharge

What could this mean for your horse?



WIN!

£50.00 Joules Gift Card...

See inside for details

Lice and Mites

All you need to know about these external parasites



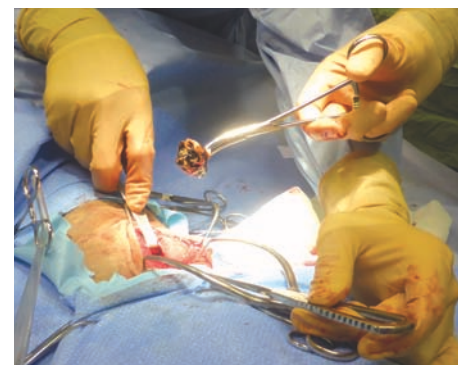PPID update

Understanding this hormonal disease affecting horses



Equine Choke

Oesophageal obstruction, problems encountered



Tetanus in horses

The importance of regular tetanus vaccinations

Working together to build a **Picture of Health**



XLEquine veterinary practices believe that prevention is better than cure. Talk to your local XLEquine veterinary surgeon about preventative healthcare so together we can ensure your horse is a complete **Picture of Health**.

T: 01228 711788 www.xlequine.co.uk



contents

Winter Edition 2018

the editor

Hello and welcome to the Winter edition of Equine Matters.



This issue of Equine Matters finds me writing my welcome on board a train home from a Continuing Professional Development course in the Midlands.

As vets, we are required to undertake a significant number of hours of further learning each year to allow us to remain practising. Although this may be a requirement, updating our knowledge and skills to offer the best care possible to you and your horses is also a cornerstone of XLVets Equine. I very much hope that via Equine Matters we can also help to keep you, as horse owners, up to date with the ever-changing face of equine veterinary care. With that in mind, we have a variety of topics in this edition, including an update on PPID (formerly known as Cushing's disease) - it's not all old ponies with teddy-bear coats we are talking about here either, and some very thought-provoking information about equine genetic diseases that you may not have ever considered before. And finally, we wish all our readers a merry Christmas and a happy, healthy 2019.

Susan Donaldson Clyde Vets

03

Equine lice and mites

Caroline Blake from Torch Equine Vets provides an explanation of the differences between lice and mites, and advice on how best to control them.

05

Investigation of a nasal discharge

Colin Mitchell of Scott Mitchell Associates describes the common causes and categories of nasal discharge, and the investigation techniques used.

07

An update on PPID

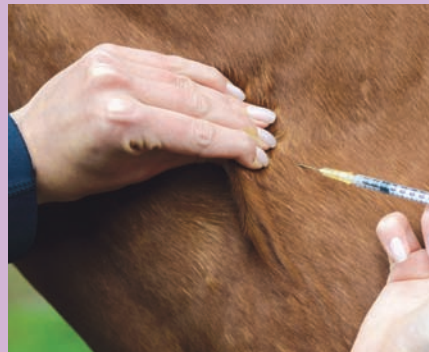PPID used to be called Equine Cushing's Syndrome. Rachel Pretswell of Northvet Veterinary Group gives us an update on this increasingly common condition.

09

Disease prevention

Tetanus in horses

Tom Southall of DS McGregor & Partners details this distressing and often fatal disease.



11

Equine genetic diseases

Lizzie Royce of Hook Norton Veterinary Group explains how genetic diseases are inherited and describes four disorders caused by defective genes.

13

Oesophageal obstruction (Choke)

Gillies Moffat from Seadown Veterinary Services describes the causes of this common problem and the treatment options.

15

Nursing the infectious horse

Richard Meers of Fellowes Farm Equine Clinic explains the necessary precautions and care requirements when dealing with an infectious, ill horse.

17

Respiratory conditions

Abnormal respiratory noises

Keesjan Cornelisse from Calweton Equine describes a range of respiratory conditions and the noises they create.



19

Happy endings - Respiratory noises

Keesjan Cornelisse from Calweton Equine tells the story of Cleopatra, a one-day-old Arab filly, who was snorting and choking on her milk.

20

Happy endings - a lameness case

Charlie Mitchell of Cedar Veterinary Group reviews the case of Flash, an eight-year-old pony who, thanks to his owner's patience and high standard of care, made a full recovery from a serious foot problem.

XLVets Equine is a group of 27 equine practices spanning the length and breadth of the UK. We work together to share experience, knowledge, ideas and skills in order to define and deliver the highest standards of equine health, care and welfare.

Equine Lice and Mites

All you need to know about these irritating external parasites



As the colder months approach us, we no longer have the worry of the flies and midges of summer; in the winter months however, there are other external parasites that can cause clinical problems in the horse.

The most common of these are lice and mites. There are important differences between lice and mites that all horse owners should be aware of.

Lice

There are two different lice types that commonly affect horses in the UK: the sucking louse - *Haematopinus Asini*, and the biting or chewing louse - *Damalinia Equis*.

The sucking louse tends to be larger (4-5 mm long) and feeds by sucking the blood at the root of the long mane and tail hairs.

The smaller biting louse (1.5-2 mm) (Figure 1) feeds on dead skin cells causing intense irritation and tends to move around the body more especially in the flank and neck areas.



Figure 1: *Damalinia Equis*

Lice thrive in the horse's denser winter coat and numbers reduce after coat shedding in the spring.

Lice tend to affect horses with a less robust immune system and so more commonly the younger or older animals are affected. Horses with underlying disease such as PPID (see page 7) or malnourished animals also tend to be more severely affected.

Lice live their entire life-cycle on the horse. The eggs are laid and stick to the base of the hair where they hatch into larvae and grow into adults.

The eggs take 2-3 weeks to hatch, which is important to remember when treating these horses. The whole life cycle from egg to egg laying adult can take 30 - 40 days.

Clinical Signs

Horses with lice are primarily itchy. They will constantly rub their mane or tails and may chew at themselves (Figure 2).

The horse may appear restless. The hair-coat is often dull, with flaky dandruff visible. There may be patchy hair-loss and bare areas. In more severe cases horses will rub areas of skin until they become raw and bleeding. Scabbed areas may be apparent, as well as thickened skin patches.

Very severe infestations may lead to anaemia due to the lice sucking blood, and such horses fail to thrive and may be in poor body condition.



Figure 2: Horse chewing flanks



Caroline Blake
BVSc Cert ES (Soft Tissue)
MRCVS
Torch Equine Vets

The winter months present the risk of external parasites that can cause problems in the horse.

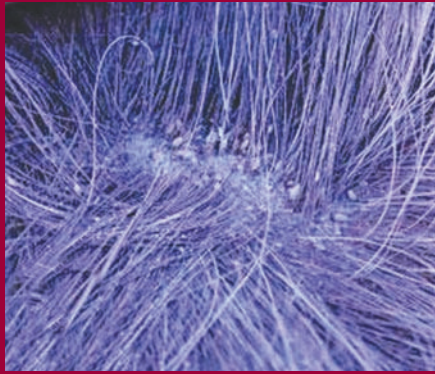

Figure 3: Lice in hair coat

Diagnosis

Diagnosing lice on your horse does not require a vet, just a careful examination of the hair coat and good eyesight!

Living lice can be seen with the naked eye, as small flattened wingless insects that are yellow-brown in colour. They are easier to see if you part the hair coat and look carefully at the base of the hairs, particularly on the mane and tailhead (Figure 3).

The lice eggs may also be seen as small white oval structures stuck to the hairs near the base of the hair-shafts.

Treatment and control

Treatment of lice is relatively straightforward and usually requires an insecticidal formulation such as a spray, shampoo or spot-on to be applied directly onto the horse's coat. The active ingredients are usually based on permethrin or pyrethroids, and kill the adult lice and so in all cases it is advisable to repeat treatment after 14 days to ensure that any further lice which hatch from eggs are also then killed.

Cypermethrin is used in a diluted form and sponged or sprayed onto the coat.

Other recommended treatments include pyrethroid-based insecticidal shampoos.

Spot-on/pour-on treatments containing permethrin can also be very useful when it is inconvenient or difficult to bathe or spray.

Some spot-on treatments containing deltamethrin can be very effective but are not licensed for use in horses and should only be used under veterinary supervision.

Mites

The most clinically important mite in horses is the feather mite - *Chorioptes Equi* (Figure 4).

Choriotic mites are far smaller than lice and not visible to the naked eye. They live on the horse's hair and skin and can deep burrow into the skin causing intense irritation. These mites particularly love to inhabit the long hair on the limbs of rough legged animals, typically the heavy feathered legs of cobs and the heavy horses. The condition may also be known as heel mange, chorioptic mange or feather mites.

As with lice, the life cycle is completed from egg to adult on the horse within approximately 2-3 weeks.

Clinical Signs

Affected horses are usually very itchy. Typically, they will stamp and rub at their legs and may bite and chew them. Raw sore patches may develop on the back of the fetlock and pastern areas and the back of the knee (Figure 5). Often the skin also becomes very flaky. In more chronically affected animals the skin of the lower limb can become thickened and this can make the condition more difficult to treat. In more severe cases the mites can spread all over the body.

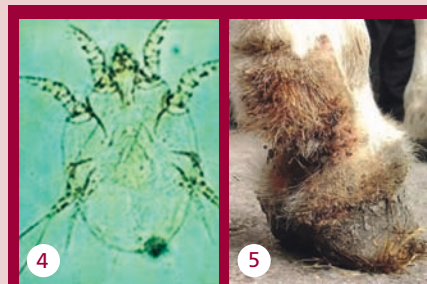

Figure 4: Chorioptic mite

Figure 5: Chorioptic mange

Diagnosis

Unlike lice, mites cannot be seen with the naked eye. Therefore, diagnosis relies on your vet taking coat brushings or sellotape strips from the affected areas and examining them under a microscope. However, even then live mites may not be apparent.

Based on the history and clinical signs, treatment will often be initiated even if live mites have not been detected under the microscope.

Treatment

Successful treatment of feather mites can be more difficult than lice as some horses may be infected without showing clinical signs, thereby providing a source of re-infection for those horses which have been treated. Re-infection can also occur due to the ability of the mites to live in the environment off the host for several days in dark warm conditions. Cleaning and disinfecting the stable and removing and replacing bedding is therefore important.

There is currently no licensed veterinary product to treat chorioptic mange in horses, however the off-licence use of doramectin injection has proved effective. This should only be administered by your vet who will ensure accurate dosing and provide advice on potential side-effects. It is also advisable to repeat the injection after about 2-3 weeks in order to effectively reduce the mite population.

To further reduce the numbers of mites present, especially in more severely affected cases, it is advisable to closely clip the feathers off.

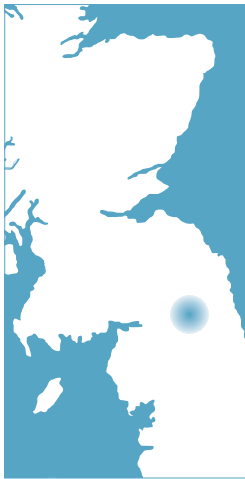Topical washes with sulphur or ivermectin can be helpful especially if sponged onto clipped limbs. Also, certain preparations containing fipronil have been shown to have some effect, however they are unlicensed for horses so should only be used under veterinary supervision.

In all cases, it is best to ask your vet to help you design a suitable treatment plan which may include a number of the treatments mentioned above, as no one treatment is 100% effective.

Early, aggressive and thorough treatment will really help to keep horses problem-free. However, it is almost impossible to completely eradicate the infestation and so it will recur in many cases, requiring ongoing management and often repeated treatments.

Investigation of a Nasal Discharge

**Scott
& Mitchell
Associates**
VETERINARY
SURGEONS



Colin Mitchell
BVM&S CertEP CertVBM
MRCVS
Scott Mitchell Associates

A nasal discharge in the horse (Figure 1) is a clinical sign which is seldom missed by owners. An owner's description of the discharge, if not present at the time of examination, can provide useful information in the investigation.




Figure 1: Purulent nasal discharge

A discharge can be categorised:

1. Mucoïd (clear or slightly white)
2. Purulent (pus)
3. Muco-purulent (a combination of the above)
4. Haemorrhagic (blood)
5. Food material / saliva

If your horse has a nasal discharge, the answers to the following questions can be helpful in determining the cause:

- Is the discharge from one nostril (unilateral) or both (bilateral)?
- What is the nature of the discharge (mucoïd / purulent / haemorrhagic or food)?
- Does the discharge have a foul smell?
- Have you noticed any swelling on the side of the horse's head?
- Is there a discharge from the eyes?
- Does your horse have a cough?
- Is the discharge related to exercise?

After a full clinical examination, a tentative diagnosis of the cause of the discharge may be possible. Horse's with 'choke' (an obstruction, usually food material, within the oesophagus between the throat and the stomach - see page 13) will usually cough frequently, appear quite distressed and there may be a history of recent feeding.

A majority of cases of nasal discharge can be resolved, eventually.






Figure 2: An endoscope

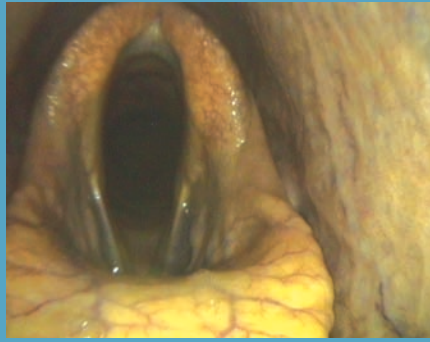

Figure 3: Endoscopic view of the larynx

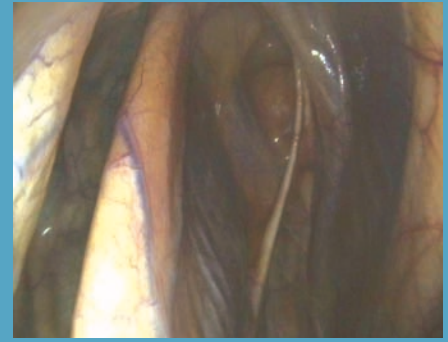


Figure 4: Endoscopic view of inside of the guttural pouch

These horses may show food material and/or saliva running from one or both nostrils. Another, less common possibility which may appear similar, is acute Grass Sickness or other causes of obstructive colic. In these horses, stomach contents/fluids may spontaneously reflux (be expelled) from the nostrils. These horses are usually quite sick and if this is seen in association with colic signs, a favourable outcome is not usually likely. This is unusual however, and quite different to the sudden onset distress seen in horses with choke.

If a small amount of blood is seen at the nostril(s) within a few hours of strenuous ridden work, this may be a sign of Exercise Induced Pulmonary Haemorrhage (EIPH). This is a condition which occurs when tiny blood vessels in the lungs rupture when large differences in pressure exist between the inside of the blood vessel and the air in the lungs. Inflammatory airway disease can exacerbate this condition. The exercise required to cause EIPH is usually a fast canter, or gallop.

In many cases, further tests such as an endoscopic examination will be needed to confirm the presence, nature, and possible source of a nasal discharge. This is a procedure where a flexible camera called an endoscope (Figure 2) is passed up the nostrils, across the back of the throat and then down into the windpipe to the entrance of the lungs. The area from the larynx (voice box) to the nostrils is known as the upper respiratory tract (URT), while the windpipe and lungs are known as the lower respiratory tract (LRT).

A source of a nasal discharge can be upper or lower respiratory tract. The endoscopic view of the larynx is shown in Figure 3.

Along this 'journey', the vet is examining the respiratory tract for swellings, the

presence of mucus, lymph node enlargement and foreign bodies. In many cases, horses will tolerate the examination very well, since their respiratory tract is not as sensitive as ours. Sedation is usually required, but not always.

During this procedure, the endoscope is likely to be passed into the guttural pouches of the horse (Figure 4). These structures are pouches on either side of the throat that form as an enlargement of the narrow tube that connects the horse's throat to the middle ear. Some respiratory infections (e.g. 'Strangles') can localise in the guttural pouches. Following infection some horses can become carriers of infection and may show intermittent nasal discharge.

The sinuses naturally drain into the back of the horse's nasal cavity, near the throat. This area can also be visualised endoscopically, confirming if a discharge is coming from the sinuses. Causes of sinus related nasal discharge include primary sinusitis, a sinus cyst, sinusitis caused by dental disease, or occasionally neoplasia (a tumour).

Another procedure that may be required is radiography (X-ray) of the head. This will allow your vet to examine the sinuses, teeth and tooth roots and ethmoid bones (a delicate arrangement of small, fragile bones at the back of the horse's nasal cavity). This procedure is usually done under sedation and a headstand may be

used to hold the head at different heights and positions. Various views will be taken of the head to ensure the area of interest is thoroughly examined.

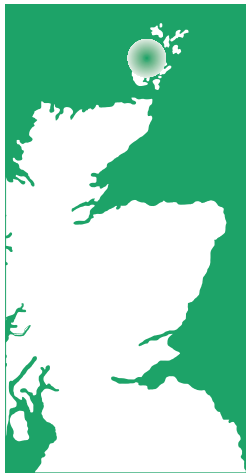If there are inconclusive findings at this stage in the investigation, a computed topography (CT) scan may be recommended. This is a form of advanced imaging which allows the bony and soft tissues of the head to be examined. Images are taken at various 'slices' across the head, then a computer can 'build up' these sliced images to provide an image of the whole.

The common causes of nasal discharges are:

- EIPH
- Choke
- Respiratory infection
- Inflammatory airway disease
- Primary sinusitis
- Sinusitis secondary to dental disease
- Guttural pouch disease

A logical investigation, utilising further diagnostic tests where required, does, in most cases, lead to an accurate diagnosis. From this, a management plan can be worked out to treat the discharge appropriately. Most cases of nasal discharge can be resolved, eventually.

An update on PPID



Rachel Pretswell
BVMS MRCVS
Northvet Veterinary Group

Pituitary Pars Intermedia Dysfunction (PPID) is a common, chronically progressive hormonal disease affecting horses. Formerly known as Equine Cushing's disease, PPID was once thought to be a rare disease only affecting older horses.



Understanding of this disease however, has increased greatly in the past decade with advances in diagnosis and treatment allowing for better management of cases and earlier diagnosis.

PPID occurs due to dysfunction of part of the pituitary gland at the base of the brain. The pituitary gland produces many different hormones and proteins which control processes in the body and is regulated by the chemical dopamine. While the exact cause of PPID is currently unknown, in patients with PPID inadequate dopamine is produced resulting in poor regulation of the pituitary gland and over production of the hormones and proteins released there. While there are some similarities between PPID and Cushing's disease in dogs and humans, the cause, clinical signs and treatment have been found to differ hence the preferred name PPID as opposed to Equine Cushing's Syndrome.

While most cases of PPID are diagnosed in horses over 15 years old, it is now known that it can be seen in younger horses, although cases in animals younger than 10 years old are rare. The clinical signs of PPID are thought to be related to the increased levels of certain hormones produced by the pituitary gland, however the exact link has yet to be established.

Clinical signs of PPID can be grouped into early and advanced signs. These terms have no

relation to the age of the horse and refer instead to the stage of disease i.e. a 15-year-old horse can present with advanced symptoms and equally a 23-year-old horse can present with early symptoms.

Advanced signs of the disease tend to be more obvious and those that we traditionally associate with PPID including:

- **Hirsutism** - abnormal coat shedding resulting in a long curly coat
- **Abnormal fat deposits** - bulging fat pads typically above the eyes
- **Muscle wastage** - commonly seen as a loss of topline
- **Recurrent infections** - e.g. ringworm, sole abscesses
- **Increased drinking and urination**
- **Pot-bellied appearance**
- **Recurrent laminitis**

Testing of previously undiagnosed laminitic animals for PPID is extremely important.

In the past it was common for PPID not to be suspected until the animal was displaying these advanced signs of the disease (Figure 1) however, we now know that more subtle signs can be present much earlier in the disease.

These include:

- **Subtle coat changes** - abnormally long hair over the jugular groove and on the back of the legs or delayed coat shedding compared to herd mates
- **Changes in attitude/lethargy**
- **Laminitis** - can be the only clinical sign



Figure 1: A pony showing signs of advanced PPID

Of all the clinical signs of PPID, laminitis is of greatest concern. The exact cause of laminitis in PPID is poorly understood and is an area of much active research. We know that underlying PPID is extremely common in cases of laminitis with one study demonstrating as many as 70% of horses with laminitis suffering from PPID.

One theory for the link between PPID and laminitis is that many horses with PPID show insulin resistance. Insulin resistance is characterised by an abnormally high level of insulin in the blood following ingestion of dietary sugars. We know that high levels of insulin in the blood can cause laminitis but confusingly not all animals with PPID will be resistant to insulin. Regardless of the cause, we now know that in many PPID cases laminitis may be the only clinical sign meaning that testing of previously undiagnosed laminitic animals for PPID is extremely important.



Figure 2: PPID can be easily diagnosed on blood sample

A diagnosis is generally straightforward once PPID is suspected. The most commonly used test is a single blood sample looking at the hormone Adrenocorticotropic Hormone (ACTH) (Figure 2). In cases of PPID, ACTH is overproduced so a high ACTH result is indicative of PPID. Levels of ACTH are naturally higher in horses during the autumn months so results are compared to a seasonally adjusted reference range.

Basal ACTH is a quick and simple test making it the preferred test for diagnosis of PPID. However, it does have some limitations. The sensitivity of this test in older horses is not perfect meaning that not all cases of PPID will test positive. For this reason, your vet will interpret results taking into account the animal's clinical signs. If PPID is still suspected following a normal ACTH result, your vet may choose to re-test ACTH later in the year or do another test called a TRH-Stimulation test. This test involves evaluating the response of the pituitary following stimulation with a drug called Thyrotropin-Releasing Hormone. Horses with PPID will have an exaggerated response compared to normal horses. For most of the year, excluding the autumn months, this is the most sensitive test for PPID.

Treatment for PPID involves daily administration of Prascend (pergolide mesylate) tablets. This is the only licensed treatment for PPID and has proven to be

both safe and effective with an improvement in clinical signs usually observed in 4-12 weeks. Following the start of treatment your vet will retest ACTH levels to check the response to treatment. Depending on the result the dose may be increased or reduced at this point.

Side effects of Prascend are few and generally transient. The most common issues relating to Prascend treatment are a reduction in appetite and difficulties in administration due to poor palatability of the tablets. Poor appetite is generally a temporary issue however, if this is not the case your vet may choose to reduce the dose. Administration of the tablets can be difficult with horses often finding the tablets when hidden in feed. For some horses hiding the tablet in a piece of apple or carrot may be sufficient but for particularly stubborn patients your vet may be able to give you empty gelatine capsules to hide the tablet which should disguise the taste.

Unfortunately, there is no known way to prevent PPID. However, with prompt diagnosis and appropriate management there is no reason a horse with PPID can't continue to lead a normal life.

Tetanus in horses



Tom Southall
BVM&S MRCVS
DS McGregor &
Partners

Tetanus is a disease of mammals caused by the harmful toxins that can be released by the bacterium *Clostridium tetani*. Of the domestic species affected, horses are the most susceptible, whereas dogs and cats are more resistant.

The *Clostridium tetani* bacteria are widespread. They can be found in the digestive tract of many animals, including horses and man, and their spores can be found in soil, particularly in soils that have been cultivated. These spores are highly resistant in these environments and can survive for many years.

The disease generally occurs after the bacteria invade the susceptible horse's body via a wound. Given the right conditions, the bacteria can then produce their harmful toxins, which affect the nervous system. Any wound can allow entry of tetanus, but deep penetrating wounds, such as a puncture to the hoof, are more liable to permit proliferation of the bacteria. This is because the bacteria favour low oxygen (anaerobic) conditions, as can be found in deep punctures, hoof wounds and dead (necrotic) tissue. Other common sites include surgical wounds (e.g. post castration), umbilical cords in young foals and retained placentas in the mare. The nature and conditions of the wound also influence the amount of toxin that is produced, and hence the severity of the symptoms that develop.

Clinical signs:

The symptoms of tetanus develop after an incubation period of anything from a few days to a few weeks. The symptoms, which can be varied, are due to the effects of the tetanus toxin on the horse's nervous system, where they result in continual spasm of the horse's various muscles:

- Often the first sign is a change in the horse's gait, with a low foot elevation and the action becoming stilted and stiff.
- There is also a change in demeanour, the horse becoming more nervous and sensitive, reacting violently to sound, movement and touch, as these stimuli cause painful muscle spasms.
- The horse will develop an anxious expression with nostrils flared, eyes wide open, and ears erect.
- As the disease progresses, so does the severity of the muscle spasms. The horse will stand square on four stiff limbs, with the legs rigid, and the head and neck extended and tail raised. This is described as a 'saw-horse' appearance.
- The stiff neck and back means there is a reluctance to eat from the floor, and spasm of the muscles of the jaw eventually prevent eating and drinking. This symptom is known as 'lockjaw'.
- In the later stages of the disease, the horse may fall over and then be unable to get up, as all of the horse's muscles are in spasm. Further progression leads to generalised convulsions and fits, and ultimately, respiratory or cardiac arrest and death.

All equine animals should receive regular tetanus vaccinations.



Treatment:

As the more severe cases of tetanus are usually fatal, horses suffering from the disease often have to be humanely euthanised on welfare grounds.

Milder cases can occasionally be treated, but treatment must be started early and be aggressive to have any chance of success.

- Affected horses are kept in a quiet environment, with minimal light and noise.
- The intensive supportive care and nursing required may include intravenous fluids, feeding tubes as well as physical support.
- Horses also receive various painkillers and sedatives to keep them comfortable.
- Identifying the site of entry is important to limit further proliferation of the bacteria.
- Antibiotics such as penicillin are used, as is tetanus antitoxin.

Although treatment in some cases is possible, the road to recovery can be both long and expensive, as well as stressful for both owner and horse. Clearly, in the case of tetanus, prevention really is better than cure.



Vaccination

Vaccination is the only proven method of protecting against the disease. And in this country, we are lucky to have effective tetanus vaccines that are widely available and inexpensive.

There are several brands of tetanus vaccine available, and the exact protocol will depend upon which one is used. Your vet will be able to advise you in detail, but in general a primary course of two injections, given approximately 4-6 weeks apart is initially required.

The vaccines contain tetanus toxoid, an inactivated form of tetanus that stimulates the horse's immune system to produce its own antibodies to tetanus. The immunity wanes over time, and so booster vaccinations are required every 2 to 3 years in order to maintain sufficient levels of protection.

Pregnant mares are usually given a booster vaccination in the later stages of pregnancy to increase the antibodies that will be available to their foal through their colostrum. This will give temporary protection to the foal, who should then receive their own primary vaccination course once they are 4-6 months old. Tetanus antitoxin can also be used to give more rapid protection for unvaccinated horses which suffer a condition making them susceptible to tetanus. It is important to realise that this offers short-lived protection only and does not replace vaccination.

Of course, if we could keep our horses from ever getting a wound, that would go a long way towards preventing the disease also. Sadly, this is not practical. However, promptly identifying any wounds, especially deep wounds, so that they can be cleaned and receive appropriate veterinary management, will help reduce the risk. This is particularly important in the unvaccinated horse.

Vaccination schedule:

Primary course of two injections of tetanus toxoid vaccine given 4-6 weeks apart.

This can be started in foals from 4-6 months of age.

Booster injections required every 2 - 3 years.

Pregnant mares should receive an additional booster in their last trimester.

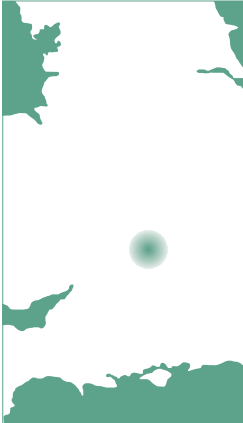Your vet will give you specific guidelines based on the brand of vaccine being used.

Summary

Tetanus is a very distressing and usually fatal disease in the horse. Fortunately, in this country it has become a rare occurrence. This is largely thanks to the widespread use of effective vaccinations, either alone or in combination with vaccination against equine influenza. However, the tetanus bacteria are still present in the environment, and so owners are encouraged to ensure their horses continue to receive regular tetanus vaccinations as outlined by their local vet.

Equine genetic diseases

HN VG Hook Norton
Veterinary Group



Lizzie Royce
BVSc MRCVS
Hook Norton
Veterinary Group

A genetic disease is a disease which is caused by a specific mutated gene and is passed directly from the sire or dam to the foal in its DNA (inherited). Genetic diseases may be caused by a recessive or a dominant gene.

For a recessive condition, the individual horse must inherit two copies of the defective gene in order to show the disease whereas for a dominant condition only one copy is required, making disease more likely. Fortunately, many genetic diseases in horses are caused by recessive genes and are therefore seen less frequently (Figure 1).

Warmblood Fragile Foal Syndrome (WFFS)

WFFS affects approximately 7-8% of Warmblood foals causing them to be born with extremely thin and fragile skin.

Signs include:

- Skin lesions all over the body but particularly on pressure points such as the limbs, withers and joints
- Hyperextension of limb joints
- Accumulation of fluid or air under the skin or in body cavities
- Haematoma (A swelling filled with blood)

Severely affected foals are often euthanised shortly after birth due to their very poor prognosis. A genetic cause of the disease has been definitively determined only in the last five years. The mutation responsible is in the PLOD-1

We look at a few of the equine genetic diseases caused by a specific mutated gene passed on in DNA.

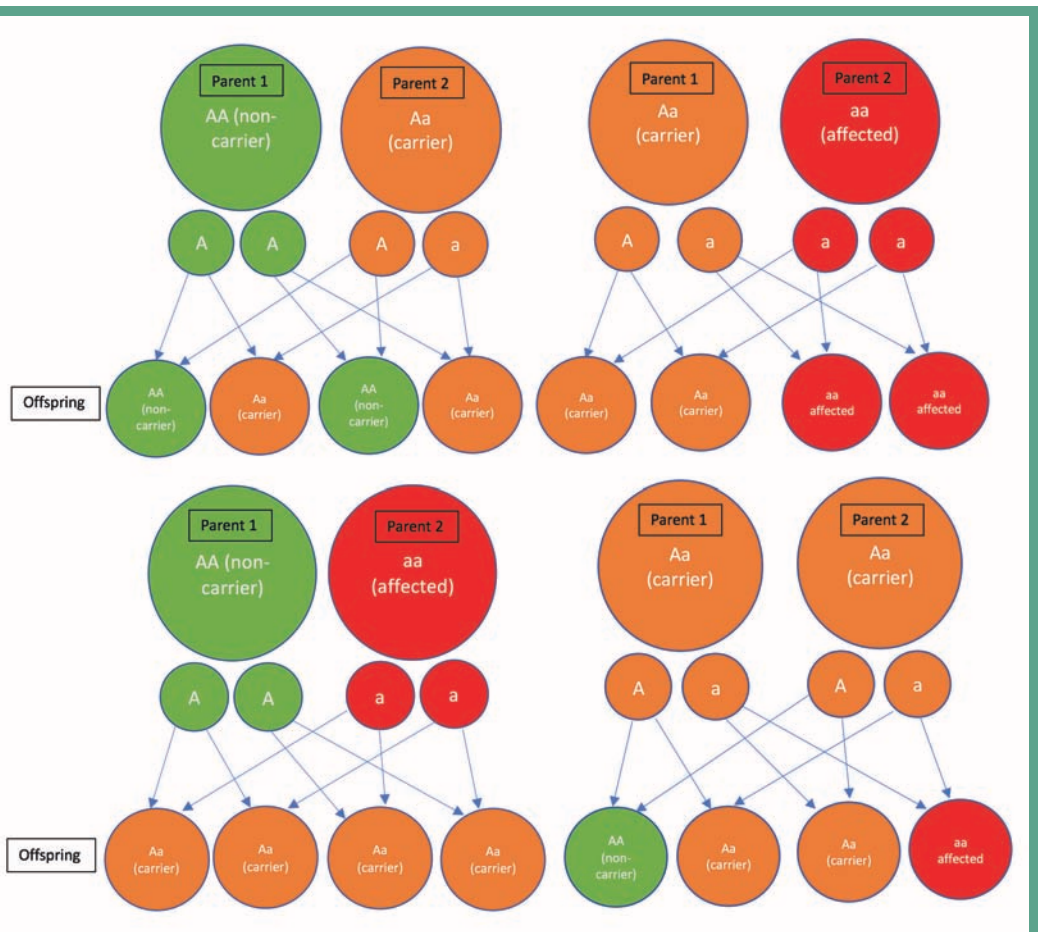


Figure 1: Genetic diagrams showing some of the possible outcomes when breeding two parent horses of different genetic status. 'A' denotes a dominant (healthy) allele whilst 'a' denotes a mutant (disease-causing) allele

gene, which plays an important role in the synthesis of collagen and the crosslinking required for strength and stability of collagen fibres in the skin. The condition is recessive, meaning that a copy of the defective gene must be inherited from both the dam and the sire in order for a foal to be affected. Both parents will most likely appear clinically normal. Interestingly, mutations in the same gene in humans are known to cause a similar condition called Ehlers-Danlos Syndrome. Fortunately, a genetic test is available for this condition and Warmblood broodmares and stallions should be tested prior to breeding. All active KWPN-approved breeding stallions have been tested for the condition this year and the results of this test are publicly available on the KWPN website. It is important to note that carrier stallions can and should still be bred from, but only to a non-carrier mare. Non-carrier stallions may be bred to either a carrier mare or a non-carrier mare.

Polysaccharide Storage Myopathy (PSSM)

PSSM can affect any breed of horse except for full thoroughbreds. Breeds such as Belgian Drafts, Quarter Horses and Warmbloods tend to be affected more commonly than other breeds. Typically horses with PSSM look as though they have 'tied up' showing signs such as hindlimb muscle stiffness, reluctance to move, painful, swollen muscles and sweating up. However, in contrast to tying up, PSSM is caused by a genetic mutation in the glycogen synthase enzyme (GYS1) which leads to higher than normal glycogen concentrations in skeletal muscle. Unfortunately, this condition is caused by a dominant gene, meaning that only one copy of the mutated gene must be inherited to cause disease. This may be inherited from either the dam or the sire and so affected animals should not be bred from. The condition can be diagnosed by a combination of:

- Blood sampling to measure the levels of muscle enzymes released in response to muscle damage
- Muscle biopsy (taking a small sample of muscle tissue and examining it under a microscope following special staining)
- Genetic testing



Figure 2: Dio owned by Debbie Clarke, competing successfully despite having PSSM

There is no 'cure' for the condition but management is usually successful and consists of a special high fat, low starch diet and an established exercise routine with consistent daily exercise, good warm up periods, no rest days, plenty of turnout and no breaks in routine. Many horses are able to be ridden and compete successfully if the condition is well managed (Figure 2).

Hoof Wall Separation Disease (HWSD) in Connemara Ponies

HWSD is an inherited genetic disease affecting Connemara ponies. It is caused by a single gene mutation and the condition is recessive. In affected ponies the outer layer of hoof wall loses connection with the inner layers leading to cracking and breaks (Figure 3). All four feet are usually affected and clinical signs begin to appear when ponies are young. Ponies often become lame, develop abscesses and laminitis and don't hold shoes well. Depending on the severity of the condition, some ponies may be able to stay in work but the most severe cases may require euthanasia. There is no 'cure' for the disease but some less severely affected ponies may be able to be managed with a combination of remedial farriery, dietary supplementation and modified living conditions. Genetic testing for this condition has been available since 2014 and allows categorisation of ponies as either carriers (one copy of the gene), affected (two copies of the gene), or negative (no copies of the gene). As with Warmblood Fragile Foal Syndrome, carrier ponies can still be bred from but only to ponies which are known to be genetically negative for the condition.



Figure 3: A case of hoof wall separation disease. (Photo by permission of Ben Benson AWCF)

Foal Immunodeficiency Syndrome (FIS) in Fell and Dales ponies

Foal immunodeficiency syndrome is a relatively recently recognised condition and can affect both Fell and Dales ponies. Affected foals appear normal at birth but quickly become severely unwell over the first few weeks or months of life, usually dying within three months. The condition causes severe immune system deficiency with a lack of white blood cells (important in fighting infections and disease), a lack of red blood cells (anaemia), and severe damage to other important components of the immune system. In all foals, important maternally-derived antibodies must be received from the dam through colostrum (first milk). These provide protection against disease for a short time after birth and as this protection wanes foals must begin to produce their own antibodies. Normal foals are able to do this but foals affected by FIS are not. FIS foals are therefore unable to fight infection and disease and so are quickly overwhelmed as the protection from their dams decreases.

Signs of FIS include:

- Dullness and depression
- Diarrhoea
- Weight loss
- Nasal discharge, coughing and pneumonia

Treatment of these foals is unsuccessful and they will often die or be put to sleep within three months of birth. Genetic testing is available and the condition is recessive (two copies of the gene must be inherited to cause disease, see Figure 1). Due to the already small gene pool of Fell and Dales ponies, it is important that carrier animals are not excluded from breeding completely but instead should be bred to non-carrier animals only.

Oesophageal Obstruction (Choke)

Oesophageal obstruction, or choke, is a commonly encountered problem in equine practice, and may be primary or secondary; this article will concentrate on the primary causes.



What is Choke?



Gillies Moffat
BVSc BSc GP Cert(EP)
MRCVS
Seadown Veterinary
Services Ltd

Choke refers to an obstruction in the horse's oesophagus (gullet) rather than in the airway (trachea) and as such, although dramatic in appearance, is not the immediate life-threatening emergency it is in humans, and a significant proportion of chokes resolve themselves.

However, complications, which can include aspiration pneumonia, oesophageal damage/scarring, or possible rupture of the oesophagus, are indeed serious if an obstruction is not cleared. Ultimately these complications and the fact that the horse cannot eat or drink can, in very rare cases, lead to the death/euthanasia of the horse.

Horses chew (masticate) food until it forms a bolus, and then push this bolus to the back of the mouth (pharynx). As the horse swallows, the epiglottis moves up and the cartilages in the voice box (larynx) close, thus preventing food from entering the trachea; the oesophageal sphincter then opens allowing food to travel from the pharynx to the oesophagus.

The bolus moves down the oesophagus (which is on the left side of the neck), through the chest cavity and into the stomach.

Obstructions tend to occur in certain regions, where the diameter of the oesophagus narrows and/or changes direction. Most obstructions occur in the cervical (upper) oesophagus; the oesophageal entrance to the chest cavity (thoracic inlet); and occasionally at the entrance of the stomach (cardiac sphincter).



Primary Causes:

Although foreign bodies may be involved e.g. twigs or brambles, primary obstruction is most commonly caused by impaction with feedstuffs. Inadequately soaked feed such as sugar beet pulp or cubes which continue to swell and inadequately or inappropriately chopped carrots and apples are frequent causes of obstruction.

Dental problems in the older horse such as missing teeth, large hooks, or wave mouth can prevent adequate mastication of the food before swallowing; in young horses erupting teeth or deciduous caps can lead to oesophageal obstruction (Figure 1).

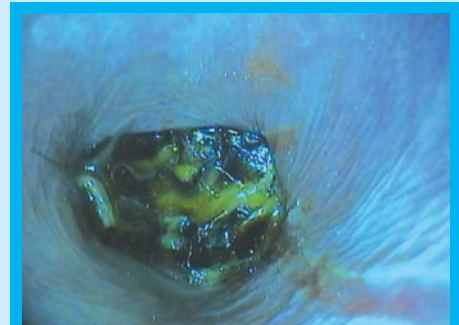


Figure 1: Tooth fragment causing oesophageal obstruction

Choke is often seen in hierarchical scenarios, e.g. the situation where a horse bolts its feed so that it does not lose out to another horse, or so that it can push another horse away from their food.

Sedatives and anaesthetics affect the co-ordinated muscular motility of the oesophagus. Therefore, horses recovering from heavy sedation or general anaesthesia that are prematurely permitted access to feed may become obstructed.

Dehydration and exhaustion may predispose a horse to oesophageal obstruction.

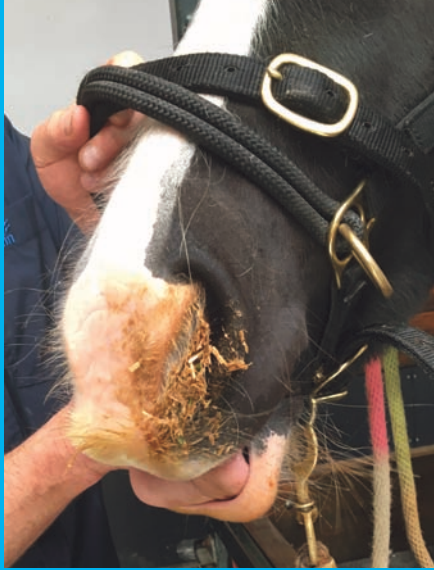

Figure 2: Nasal discharge containing food matter

Secondary Causes:

These include oesophageal strictures, diverticulum or megaesophagus; problems with the motility of the oesophagus; neurologic disease affecting the nerves involved in swallowing e.g. guttural pouch mycosis.

Signs of choke include:

- Distress - the horse may panic at the initial inability to swallow.
- Not interested in food.
- Repeated extension of the head and neck.
- Difficulty swallowing.
- Coughing.
- Nasal discharge containing saliva and/or food material (Figure 2).
- Saliva drooling from the mouth.
- Sweating in the neck region.
- If the obstruction is in the cervical oesophagus, it may be palpable.

Conditions that can present with similar signs include:

- Grass sickness.
- Botulism.
- Oesophageal diverticula (a pouch that protrudes outward in a weak portion of the oesophageal lining).
- Congenital defects.
- Gastric ulceration in foals.
- Pharyngeal trauma/abscess.

Diagnosis:

The diagnosis of oesophageal obstruction is based upon clinical signs, an accurate history particularly with reference to recent feed intake, and clinical examination.

Treatment:

Initial management involves the prevention of further intake of food or water and allowing the horse to 'relax' quietly in a stable or small area. Frequently mild cases of choke will resolve spontaneously within 30 minutes or so.

If, however, the horse is significantly distressed, or the obstruction does not seem to be clearing your veterinary surgeon should be contacted.

Your vet will take a history particularly in relation to the type of feed the horse has had access to, and then clinically examine your horse. This may include an examination of the mouth looking for obvious causes e.g. bits of stick, which can get stuck across the hard palate between the dental arcades; and palpating the oesophagus to try to locate a site / cause of the obstruction.

The vet will then sedate your horse which helps to relax the horse and lower its head. This makes the passing of a nasogastric tube easier, as well as relaxing the muscles of the neck and throat. Anti-spasmodic drugs may also be used for this purpose.

A nasogastric tube is then introduced through the nostril and gently passed into the pharynx and oesophagus until the site of the obstruction is located (Figure 3). Once located, warm water is then passed through the tube via a funnel or gently via pump to help flush




Figure 3: Introduction of nasogastric tube via nares

the obstructing food matter either out via the nose or down into the stomach. Sedation has a very important role in this process in that by lowering the horse's head, it reduces the risk of aspiration into the lungs.

Occasionally carbonated water is used, as this seems to help in the clearing of obstructions by either agitating the surface of obstructions such as sugar beet, or indeed by possibly gently causing a dilation of the oesophagus by positive internal pressure.

Once the obstruction is resolved the nasogastric tube will pass through to the stomach and water flows easily through the tube. Often this will be achieved quickly but be warned in some cases it may take a couple of hours! Anti-inflammatories and antibiotics may be required and your vet will then prescribe any required medication in the form of anti-inflammatories or advise further examination with an endoscope. If the obstruction cannot be cleared, the horse may be referred into the clinic or hospital for further treatment (Figure 4).

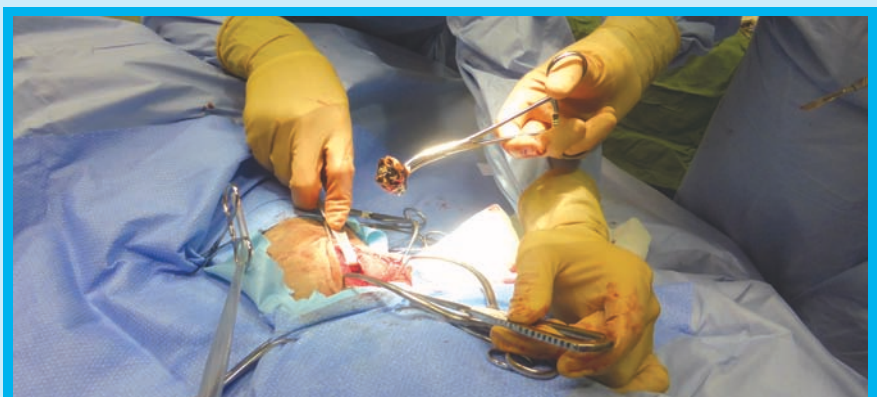
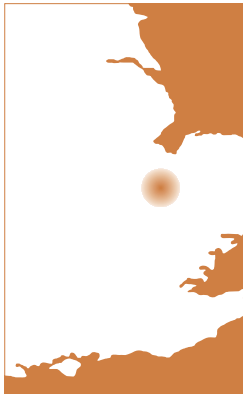
Figure 4: Tooth fragment causing oesophageal obstruction and requiring surgical removal

Nursing the infectious horse



As is always the case, it is much better to prevent disease through good management, hygiene and where available, through vaccination.



Richard Meers
 BVetMed CertAVP(ED)
 MRCVS
 Fellowes Farm Equine
 Clinic

In spite of this, if you have the misfortune to be faced with a horse suffering from a potentially infectious disease, prompt action may limit the disease's effect on your individual horse as well as minimising the risk of spread to other horses on the premises. All too often owners hope for the best case scenario and monitor the situation rather than seek veterinary advice, which may allow early intervention and minimise any greater problem in the long run.

This article will concentrate on the nursing and care of the individual horse rather than management of the disease outbreak itself. For information on outbreak control, advice from your veterinary surgeon at an early stage is invaluable. An XLVets Equine factsheet on managing a disease outbreak is also available and contains some very useful practical information.

As with people that are unwell, there are basic principles to adhere to when managing the sick horse.

Infectious diseases that may be encountered in horses in the UK at present include:

- Strangles (*Streptococcus equi subsp. equi*)
- Equine Herpes Virus
- Ringworm
- Salmonella
- Clostridial diseases
- Equine Influenza



Biosecurity is a set of preventative measures put in place to hopefully prevent or at least limit the spread of disease and is the most important consideration when nursing the infectious horse.

There are three goals of biosecurity:

- Protect the patient suffering from infectious disease as their immune system is likely to be compromised.
- Prevent the spread of the disease to other horses
- Prevent the spread of disease (if zoonotic) to humans

Some important definitions:

Zoonosis: a disease that can be transmitted to humans from animals. Ringworm, salmonella and the clostridial diseases can all potentially be passed onto staff working with infected horses.

Barrier nursing: the term given to the provision of care of potentially infectious patients includes careful consideration of biosecurity principles.

Barrier nursing protocols will exist at most equine veterinary practices but there is absolutely no reason why the same principles cannot be applied to a yard situation. It is important to apply these procedures as soon as a potentially infectious horse is noticed, not once a diagnosis has been reached. When dealing with sick horses, waterproof clothing and boots, as well as disposable gloves should be utilised. These types of clothing can be easily disinfected. Disposable suits with hoods are ideal but are expensive and should be changed frequently. A changing room or area adjacent to isolation facilities avoids clothing being worn elsewhere. Designate specific tools, water and feed buckets, head collars, rugs and brushes to infectious horses. When filling water buckets with a communal hose do not submerge the end. Ideally separate staff or an individual owner would deal with only the infected horse(s). They should not then have contact with any other horses on the yard. If this is not possible then infected horses should be dealt with after healthy horses. Any soiled bedding or disposable items should be put in bags and ideally incinerated. It is essential it is not dumped on communal muck heaps. When using disinfectants always follow the instructions on the label and choose an appropriate one for your situation. They vary in their effectiveness when contending with organic matter and hardness of water. Virkon™ is a commonly used product specifically formulated for the animal health market. Speak to your veterinary surgeon about which they would recommend. Boots, clothing and tools should be regularly disinfected. Despite wearing gloves, hands should be disinfected regularly as well. Hand sanitizer gels containing at least 65% alcohol are ideal for this purpose.

Sick horses should be housed as far away from other horses as possible in a separate



barn or stable area. If not feasible, creating a physical barrier between stables using wooden boards and putting a grill above the horse's door can be useful. Cones and tape at the front of a stable will create a further barrier alerting others not to enter the area. Signage can also be beneficial.

Ensure anyone who attends the premises is aware of the situation and any protocols put in place. Keeping quiet to avoid affecting a yard reputation for example, is only likely to make the situation worse, and usually has the adverse effect on how people view the yard in the future.

Moving on from biosecurity, it is also important to discuss the nursing needs of the infectious horse. Meeting the needs of these sick horses will lead to less severe clinical signs and a more rapid recovery. Whilst on-the-yard care of many of these patients will suffice, often horses with more severe signs (especially infectious diarrhoea cases) may necessitate intravenous fluid therapy and other medications only available from your veterinary surgeon.

As is the case with people that are unwell there are basic principles to adhere to when managing the sick horse.

Sick horses may often have a reduced appetite and although not in work at this time, it is important to encourage them to eat. Offering tasty alternatives to kick-start a horse's appetite such as warm bran mashes, molasses and carrots can be helpful, but it is important to wean back to a normal diet as soon as possible. Supplementing vitamin and minerals can help as well, as stress/disease increases the need for B vitamins, in particular.

Many conditions, particularly diarrhoea, may lead to dehydration. It is important to maintain correct hydration to allow your horse's body systems to function correctly and fight disease. To reduce the need for your vet to administer fluids via a stomach tube or intravenously, the key is to act early. Horses do not tend to like very

Nursing of the patient should include at least twice daily checks of the following:

- **Temperature** - normal range 36.5 - 38.3°C
- **Breathing rate** - normal range 8-15 breaths per minute
- **Heart rate** - 25-40 beats per minute
- **Colour of gums and capillary refill time** - it should take less than 2 seconds for the colour to return after releasing pressure applied to the gum
- **Assess hydration level** - are the gums dry; does the skin on the neck return quickly to normal after being pinched?
- **Monitor for nasal discharge or discharge from the eyes**
- **Monitor number of droppings and their consistency**
- **Monitor water intake**
- **Observe how horse is standing and general demeanour**

cold water so having slightly warm water can help. Electrolytes in water or feed are also invaluable. If offering lukewarm or water spiked with electrolytes, it is always best to offer a bucket of 'normal' water in case your horse does not like the other options.

Every horse varies in its needs for individual attention. Don't forget they are herd animals and you have isolated them from their herd companion so it is important to give them the care they need to cope with isolation and box rest. This can vary from allowing them to be able to see other horses, to toys/treat balls to regular contact with an owner for grooming, etc. A stressed horse is unlikely to recover as well as a happy horse.

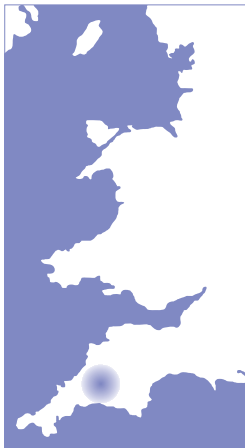As with any sick horse, your veterinary surgeon will be best placed to advise you about your individual situation.

Abnormal respiratory noises

- some common sounds and conditions explained



Under normal conditions, the breathing activity of horses can hardly be heard at rest and exercise, apart from an innocent blowing noise ('high blowing') as a result of the false nostrils vibrating as the horse breathes out.



Dr. Keesjan Cornelisse
DVM MS PhD DipL.ACVM
MRCVS

Calweton Equine
Veterinary Surgeons

Some respiratory disorders may lead to an abnormal audible noise. These noises are a result of a partial airway obstruction, either due to a physical obstruction or a part of the airway not functioning correctly. This obstruction causes the airflow to become more turbulent in the airway and hence produces an additional noise.

Abnormal respiratory noises may not necessarily be associated with reduced exercise performance. However, they are often a reason for a horse owner to consult their veterinary surgeon. Some abnormal respiratory noises may clearly be audible at rest with the ear, while other noises are only audible during exercise. Some respiratory conditions produce abnormal noises that are best detected by careful examination of the lung fields with a stethoscope.

In evaluating the presence or absence of abnormal respiratory noise, your veterinary surgeon will try to determine which part of the airway is involved. This includes considering the timing, duration and typical pitch of the noise as well as influence of exercise. Follow up diagnostic procedures will likely include standing endoscopy with a long flexible camera via the nostril into the airway when clearly audible at rest. For evaluation of noises during exercise, the horse may need to be ridden at speed or worked with an extended

or flexed head carriage to mimic the triggering conditions. This is usually followed by 'over the ground' endoscopy with a mobile endoscopy system attached to the horse whilst it performs exercise under the conditions where a noise is usually heard. Occasionally x-rays, Computed Tomography (CT) and Magnetic Resonance Imaging (MRI) may also be useful.

Abnormal respiratory noises include:

A. Coughing

A reflex-induced forced expiration caused by stimulation of irritant receptors that line the airways (Figure 1). These receptors get (over) stimulated by inhaled particles (e.g. dust, food) or in response to airway inflammation (allergy, infectious causes, smoke). As such, coughing is a mechanism to clear the airways from particles, excess mucus and inflammatory debris. Increased airflow from exercise may precipitate coughing by opening more inflamed and mucus plugged airways. Careful examination may allow identification of the affected anatomical location. For instance, cough responses after squeezing the larynx or trachea suggests upper airway involvement. A soft cough may reflect more marked disease of the lower airways or chest cavity as pain in this area restricts the coughing reflex.

B. Abnormal respiratory noises reported at rest, or audible with a stethoscope

- **Wheezes** are continuous musical noises caused by vibration of the walls of narrowed lower airways during the end of inspiration or beginning of expiration. They sometimes can be heard at the end of the horse's nostril at rest or are noticed when the chest is examined with a stethoscope. Wheezes indicate lower airway inflammation and irritation which causes them to go into constriction. In addition, overproduction of mucus adds to a decreasing airway diameter. Thus wheezes are usually associated with various degrees of laboured breathing that

'Some respiratory disorders may lead to an abnormal audible noise in your horse'

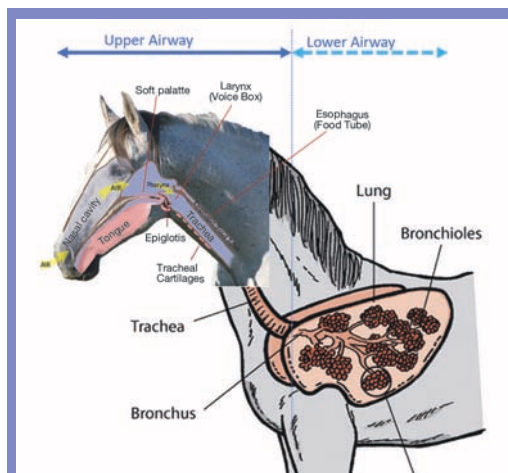


Figure 1: An overview of the equine upper and lower airway structures

may already be obvious during rest. Wheezes are therefore a common finding in horses affected with the various forms of equine asthma. This includes older horses exposed to dust and mould spores when being fed dry roughage and stabled on straw bedding (previously known as COPD) and horses struggling to breathe on hot days with high pollen counts (known as Summer Pasture Associated Obstructive Pulmonary Disease; SPAOPD).

- **Crackles** are discontinuous, explosive, 'popping' sounds that originate within the smaller airways. They are heard with a stethoscope when an obstructed airway suddenly opens and the pressure on either side of the obstruction suddenly equilibrates resulting in vibrations in the airway wall. Crackles are usually associated with obstructive airway disease (e.g. equine asthma) and some rare forms of restrictive lung disease.
- **Pleural rubs** are creaking or grating sounds that sound like walking on fresh snow. They indicate inflammation or infection of the membranes lining the chest cavity (pleuritis).
- **Lack of lung noises** may be noticed when listening to the chest. Usually this involves horses that are sick and have marked breathing difficulties.

Localised absence of lung noises indicates lack of airflow in parts of the lung that are collapsed and/or obstructed (e.g. pneumonia). Absence of the respiratory noises in the lower lung fields may indicate the presence of blood or fluid in the chest that muffles the sound. Excess free fluid may result from pleuritis (Figure 2), tumours, heart disease or severe protein loss. Lack of lung noises in the higher lung fields indicates collapse of a lung. Usually this is associated with infection (pneumonia) or chest trauma. Additional diagnostics such as ultrasound and radiographs of the thorax and an aspirate of thoracic fluid can help making a diagnosis.

- **Stridor** are loud, rather continuous noises that appear loudest over upper airways such as the nostrils, larynx and trachea. They indicate an upper airway obstruction and usually are more intense during inspiration. Assessing the nasal airflow, auscultation and endoscopy can help to pin-point an area of upper airway obstruction. Common causes include anatomical abnormalities, ethmoid haematomas, cysts and tumours (Figure 3), strangles abscesses, inflammatory oedema (smoke inhalation), foreign bodies and tracheal collapse in small equine breeds and donkeys.

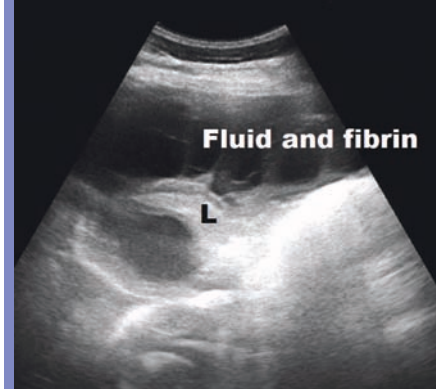


Figure 2: A folded lung lobe drifting in pleural exudative fluid resulting in muffled lung noises in the lower parts of the chest

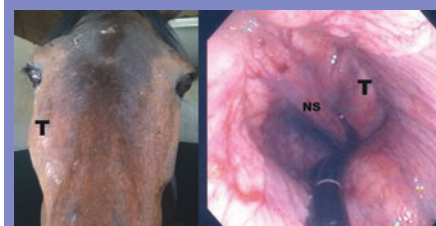


Figure 3: A horse with a respiratory stridor caused by a tumor (T) in the nasal passage. The endoscope is inserted through the left nostril and looking back from the throat area (NS = Nasal Septum)

C. Abnormal respiratory noises associated with exercise

These noises are associated with anatomical or functional abnormalities of the upper airway (nostrils, nasal passages, pharynx, soft palate, epiglottis, larynx, trachea). The noises are loud and vibrant and may sound like roaring or choking depending on location in the airway (see Table 1). They can be inspiratory and/or expiratory. Their occurrence may depend on type and intensity of exercise, level of fatigue, and head carriage. These noises may be associated with impaired exercise performance. However, this also depends on the intensity of the work being required. Diagnosis is usually made via 'over the ground' endoscopy (Figure 4).

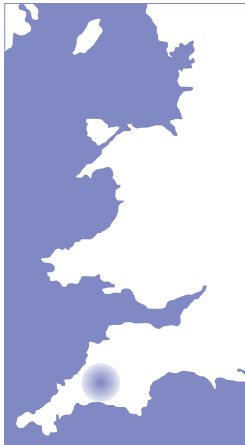Table 1: Examples of upper airway conditions associated with abnormal respiratory noise during exercise

Condition	Problem	Result	Sound description
Nostril Alar Fold Collapse	Instability of the nostril structures	Decreased functional diameter of the nostrils	A vibrant noise from the nostril region worse during expiration
Nasopharyngeal collapse	Instability of the throat	Narrowing of the throat area causing impaired airflow	Grunt or vibrant noise at inspiration and/or expiration
Epiglottis entrapment	The epiglottis is constrained by a covering membrane	Billowing membrane obstructs the larynx during expiration	A vibrant respiratory noise during inspiration and/or expiration
Epiglottic retroversion	Instability of the epiglottis position	Epiglottis sucked into laryngeal opening during inspiration	A vibrant respiratory noise
Dorsal Displacement of the soft palate (DDSP)	Instability of the soft palate	Obstruction of the laryngeal opening	A snoring/choking type of noise at intense exercise
Axial Deviation of the Alar Folds (ADAF)	Instability of small membranes connecting the larynx & epiglottis	Obstruction of the laryngeal opening	A harsh inspiratory noise
Idiopathic Laryngeal Hemiplegia (ILH)	Lazy vocal folds	Obstruction of the laryngeal opening	A high pitched inspiratory whistle type noise



Figure 4: Over the ground endoscopy

Happy Endings - Respiratory noises



Dr. Keesjan Cornelisse
DVM MS PhD Dipl.ACVM
MRCVS
Calwet Equine
Veterinary Surgeons

A newborn foal with a loud respiratory noise and nursing difficulties.

Cleopatra was a one-day old Arab filly that was seen by our practice for concerns about her occasionally making an odd noise when breathing. She was born at her expected due date and the foaling process the previous day had been uncomplicated. After delivery, Cleopatra had done all the right things such as getting up quickly, frequently nursing, passing the first dung (meconium) and passing urine.

On initial examination, Cleopatra was quite bright, but a snorting respiratory noise was sometimes audible when listening close to the nostrils. This noise was more pronounced when she was breathing out. Closer examination revealed some meconium in the nostril which was easily removed. When nursing, no milk was seen coming out of the nostrils; this suggested that a cleft palate with milk aspiration into the airway was an unlikely cause for the noise. Palpation of all the ribs ruled out rib fractures that could have caused trauma to the lungs or airways. All the lung fields sounded clear when listened to with a stethoscope. As the foal was bright and nursing well, a course of injectable antibiotics was started to protect the foal from potential infection. An anti-inflammatory was also given to help with any swelling in the airway.

However, over the following two days the noise became more marked and Cleopatra would intermittently choke when nursing (Figure 1). In addition, her cheeks would billow outwards suggesting air was coming back into the mouth (Figure 2), rather than being exhaled via the nose as it should be in horses.

In order to determine the cause of the progressive breathing noise and choke problem, endoscopy of the upper airway and throat was performed. For this, Cleopatra was mildly sedated

while a small flexible camera was passed via the left nostril into the upper throat area (nasopharynx). This revealed the presence of a 'cyst' like structure in the far edge of the soft palate (Figure 3). Subsequent x-rays were taken to determine the extent of the cyst (Figure 4). From these diagnostic procedures it became clear that the cyst lifted the soft palate over the laryngeal (voice box) opening. As a result, the soft palate edge would vibrate as the foal breathed out, creating a noise, whilst the main airflow was redirected downwards into the mouth, leading to the cheek billowing. Similarly, milk from the mouth was more difficult to swallow, hence the foal would choke intermittently.

As the noise had deteriorated with a risk for milk aspiration pneumonia, it was decided to lance the cyst using the endoscope. Again Cleopatra was mildly sedated. A special grab instrument was passed through the endoscope in order to 'nibble' away at the wall of the cyst (Figure 5). This took quite some effort as the wall was quite smooth and firm and was therefore difficult to grip. However, eventually it deflated. Over the next twelve hours, the noise, cheek billowing and choke became less marked. Antibiotic and anti-inflammatory therapy was continued for another week. By then no signs were noted and on follow up six months later, no residual signs were present.




Figure 1: The foal choking as milk can be seen dripping from the mouth

Figure 2: Cheek billowing

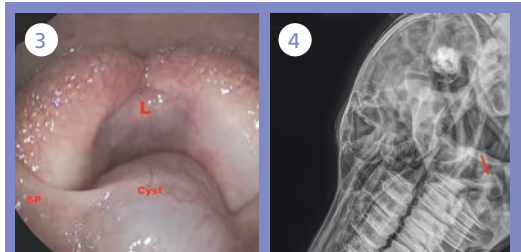
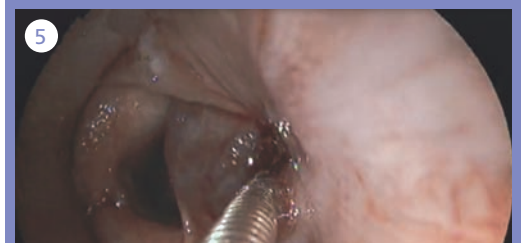
Figure 3: Endoscopic image of the throat area showing the cyst at the rim of the soft palate (SP) laying over the laryngeal opening (L)

Figure 4: X-ray of the throat area. A cyst like structure pointed out by the arrow lays over the laryngeal opening (L)

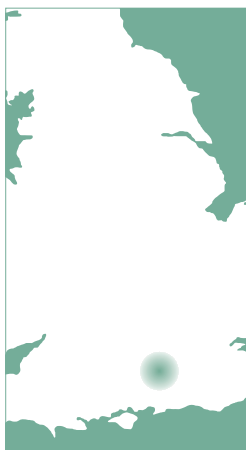Figure 5: Grabbing the cyst wall



Happy Endings - A lameness case



Cedar
Veterinary
Group



Flash is an eight-year-old pony used for pony club activities and eventing. I was called to see him a few days after he had pulled up lame after the cross-country phase at an event.

Flash presented with significant left forelimb lameness in both walk and trot, however on examination no obvious problems could be found with his leg. When his lameness didn't improve following an initial period of box rest, further investigation was needed.

Nerve blocks were performed on the lower leg to establish the location of the pain, and from this we were able to conclude that the source was within the foot. We took radiographs (x-rays) of the foot, including some additional images of the navicular bone, however these images showed no abnormalities. As a result Flash was referred to a local Equine Hospital for magnetic resonance imaging (MRI). MRI images would allow assessment of the soft tissue structures of the foot as the x-rays which had already been taken could only assess any bony abnormalities.

MRI images (Figures 1 and 2) showed a tear in the deep digital flexor tendon and inflammation of the navicular bursa (joint fluid protecting the navicular bone) and coffin joint.

This diagnosis carries a guarded prognosis for returning to the previous level of work and potential recovery would be a long and meticulously controlled process. However it was likely that we could improve Flash's chance of returning to eventing by undergoing navicular bursoscopy (keyhole surgery), which involves putting a small camera into the navicular bursa to look at the tear directly, a process which allows the torn tendon and inflammatory material to be removed.

Following his operation, Flash was restricted to box rest with walking and grazing in hand for three months to help improve the tendon healing. After a further three months of small paddock turnout, he began a gradual return to full work over four months.

Flash did very well after the surgery and became sound quickly. He never looked back from there and thanks to his owner's dedication to his careful rehabilitation, he was back jumping just a year after his injury (Figure 3).

This was a great outcome for Flash and his owners, as this type of injury can often result in a chronic low-level lameness, meaning horses cannot perform at their previous job.



Charlie Mitchell
BVSc BAEDT MRCVS
Cedar Veterinary
Group

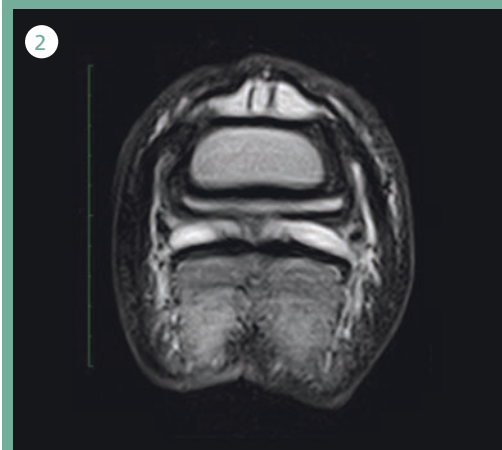
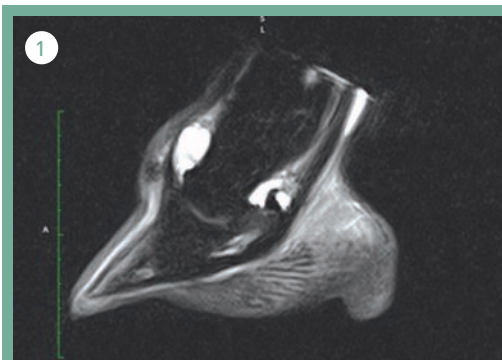


Figure 1 and 2: MRI images help diagnose the problem in Flash's foot.

Image courtesy of Liphook Equine Hospital



Figure 3: Flash show jumping a year after the initial injury



FACEBOOK COMPETITION



WIN!

£50.00 Joules
Gift Card...



Can you spot the **three**
differences between these
two photographs?

Study the photographs and find the three
differences in the bottom image. Send us
your answers via our Facebook page.

To enter please visit:

www.facebook.com/XLVetsEquine/ and list
your three answers in a direct message.

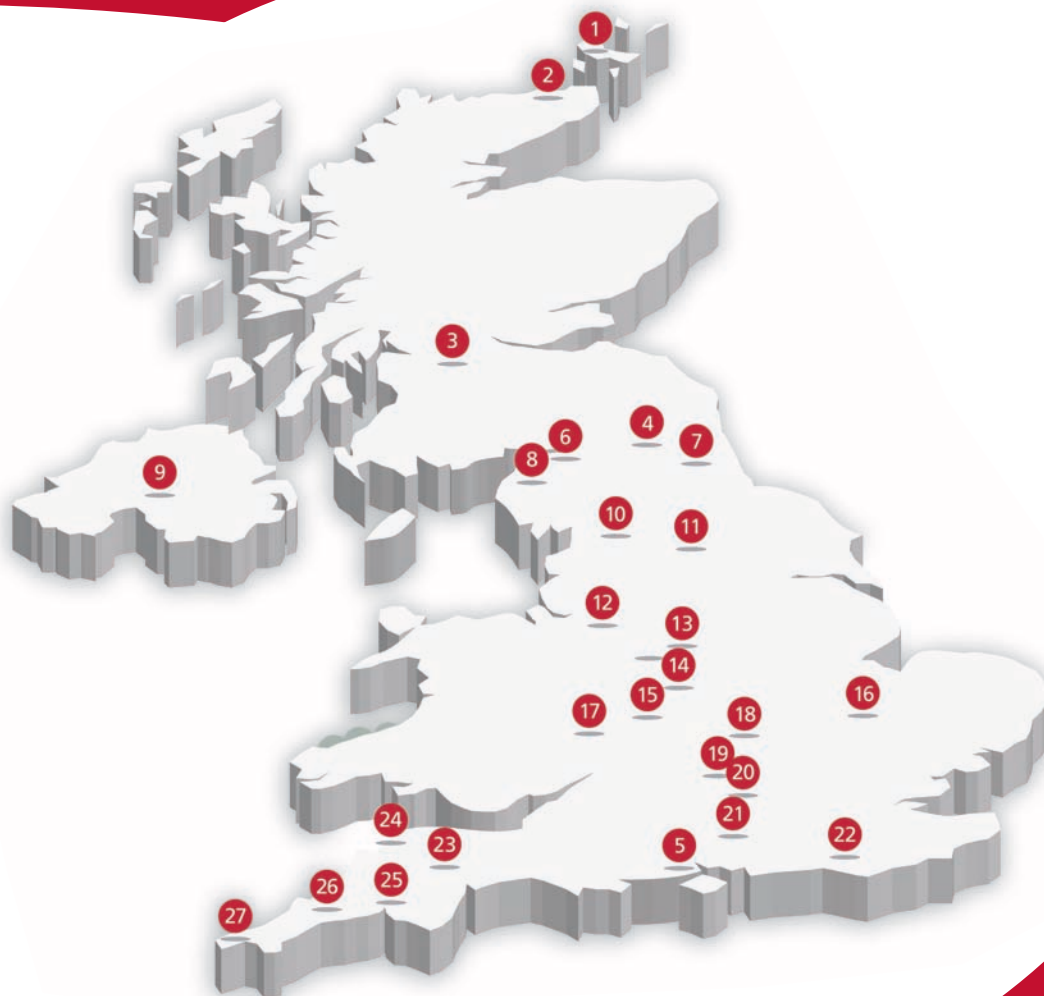Closing date: 1st February 2019

Good luck!





Our community of independent equine practices



1 Northvet Veterinary Group
Kirkwall, Orkney
Telephone: 01856 873403

2 Donald S McGregor and Partners
Thurso, Caithness
Telephone: 01847 892387

3 Clyde Veterinary Group
Lanark, Lanarkshire
Telephone: 01555 660000

4 Scott Mitchell Associates
Hexham, Northumberland
Telephone: 01434 608999

5 Seadown Veterinary Group
Hythe, Hampshire
Telephone: 023 8084 2237

6 Paragon Veterinary Group
Carlisle, Cumbria
Telephone: 01228 710208

7 Durham Equine Practice
Durham
Telephone: 0191 603 1122

8 Millcroft Veterinary Group
Cockermouth, Cumbria
Telephone: 01900 826666

9 Parklands Veterinary Group
Cookstown, Northern Ireland
Telephone: 028 867 65765

10 North West Equine Vets
Rathmell, North Yorkshire
Telephone: 0808 168 5580

11 Bishopton Veterinary Group
Ripon, North Yorkshire
Telephone: 01765 602396

12 Wright & Morten
Macclesfield, Cheshire
Telephone: 0845 8330034

13 Scarsdale Veterinary Group
Derby, Derbyshire
Telephone: 01332 294929

14 Midshire Veterinary Group
Nuneaton, Warwickshire
Telephone: 02476 384064

15 608 Farm & Equine
Rowington, Warwickshire
Telephone: 01564 783404

16 Fellowes Farm Equine Clinic
Huntingdon, Cambridgeshire
Telephone: 01487 773333

17 Belmont Vets
Hereford, Herefordshire
Telephone: 01432 370155

18 Buckingham Equine Vets
Milton Keynes, Buckingham
Telephone: 01908 560789

19 Hook Norton Veterinary Group
Banbury, Oxfordshire
Telephone: 01608 730085

20 Larkmead Veterinary Group
Wallingford, Oxfordshire
Telephone: 01491 651479

21 Cedar Veterinary Group
Alton, Hampshire
Telephone: 01420 82163

22 Cliffe Veterinary Group
Lewes, East Sussex
Telephone: 01273 473232

23 St Boniface Veterinary Clinic
Credon, Exeter
Telephone: 01363 772860

24 Torch Farm & Equine
Ilfracombe, Devon
Telephone: 01271 879516

25 Calweton Veterinary Group
Callington, Cornwall
Telephone: 01579 383231

26 Kernow Veterinary Group
Bodmin, Cornwall
Telephone: 01208 72323

27 Rosevean Veterinary Practice
Penzance, Cornwall
Telephone: 01736 362215