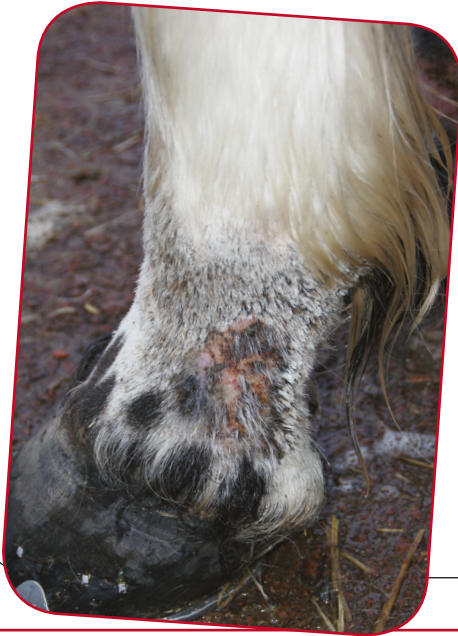


Pastern Dermatitis



Pastern dermatitis means inflammation of the skin of the pastern between the fetlock and the hoof. It is a description of a clinical appearance rather than a specific diagnosis. There are a large number of causes of pastern dermatitis. Effective treatment will depend on accurate diagnosis of the inciting factors, although this can be difficult as the skin inflammation may look fairly similar irrespective of the cause.

Causes of Pastern Dermatitis

- mud fever- infection with *Dermatophilus* bacteria;
- leg mites- Chorioptic mange;
- harvest mites - *Trombicula autumnalis*;
- ringworm - usually *Trichophyton* or *Microsporum* spp;
- folliculitis- deep infection of hair follicles with *Staphylococcal* bacteria;
- vasculitis- severe autoimmune disease of white skin on the limbs;
- photosensitisation- white skin becomes badly burned despite normal UV light exposure, usually due either to liver disease or the ingestion of certain toxic plants;
- there are also a few other rare causes of pastern dermatitis.



PHOTOSENSITISATION IS A CAUSE OF PASTERM DERMATITIS

CLINICAL SIGNS

The clinical signs are usually visible on a close examination of the pastern area but this can be more difficult in the heavily feathered breeds.

The signs of dermatitis are most commonly redness of the skin, scabs, crusting and pain in the area affected.

In some cases e.g. chorioptic mange the skin is very itchy and rubbing/ biting the area and foot stamping may be seen.

In severe cases there will be swelling of the leg and lameness which can vary in severity from mild to severe.

The swelling and lameness often improve with exercise and worsen after standing.

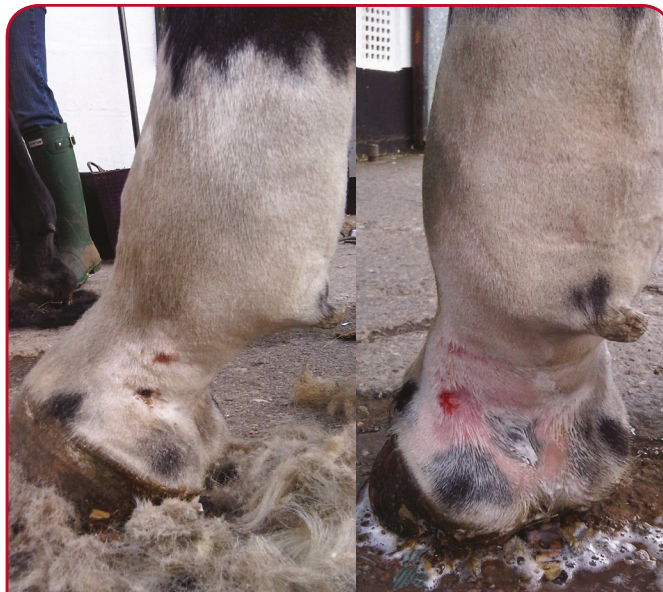KEY POINTS:

- Pastern dermatitis is not a diagnosis in itself, but describes a collection of diseases affecting the skin of the lower limb.
- Varying levels of pain, itching or lameness may be present depending on the cause.
- Identification of the underlying disease is the key to successful treatment.
- Diagnosis is easier if the condition is seen by your vet earlier rather than later.

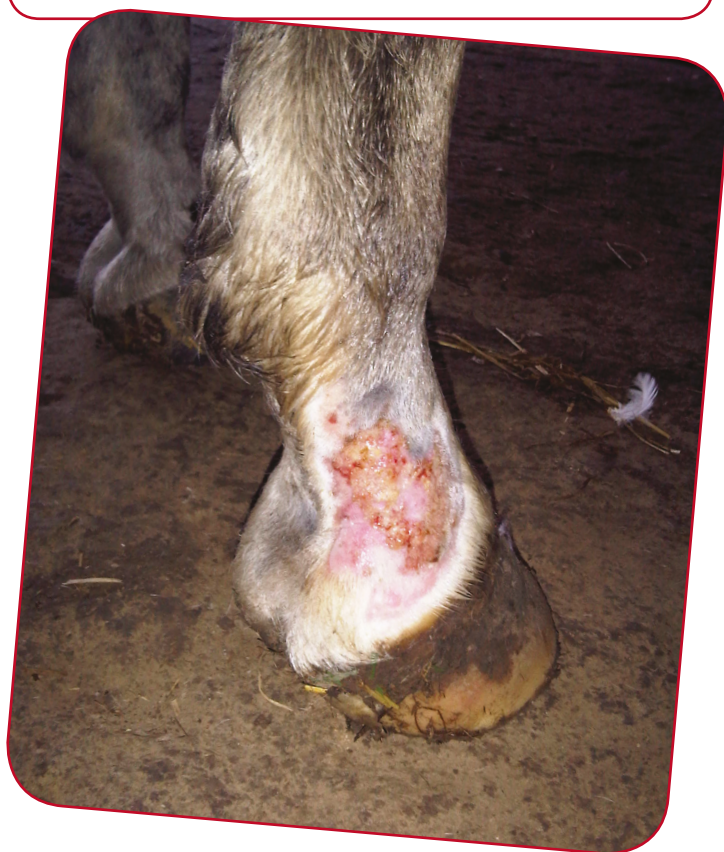Diagnosis

- In some cases it may be possible for your vet to make a diagnosis based on clinical appearance alone, but often other tests are required, such as:
- skin scrapes
- sticky tape samples
- swabs for fungal or bacterial culture
- biopsy
- blood sample.

Long-standing cases which have already received some treatment are likely to be the most difficult to diagnose accurately, so it is advisable to seek professional help early. Sometimes a secondary infection can be present as well as the original disease.



TREATMENT USUALLY INVOLVES CLIPPING THE HAIR FROM THE AFFECTED AREA AND CLEANING WITH MILD ANTISEPTIC SOLUTION



TREATMENT

The following general principles for treatment apply to most cases but specific treatment options will vary depending on the cause of the dermatitis.

- The limbs should be kept dry, so stabling may be necessary.
- Feathers may need to be clipped to get good access to the skin.
- If a parasite, bacteria or fungus is suspected, specific medication can be used.
- Cream or oil may be needed to aid scab removal, which can be very painful.
- A dilute antiseptic solution can be used to gently clean the skin.
- A topical antiseptic, antifungal or steroid cream may be useful.
- If sunlight is aggravating the condition, bandaging can be used to prevent exposure.



XLEquine is a novel and exciting initiative conceived from within the veterinary profession made up of independently owned, progressive veterinary practices located throughout the United Kingdom, members of XLEquine are committed to working together for the benefit of all their clients.
© XLVet UK Ltd.

No part of this publication may be reproduced without prior permission of the publisher.

For further information contact your local XLEquine practice:

www.xlequine.co.uk

Go to www.xlequine.co.uk