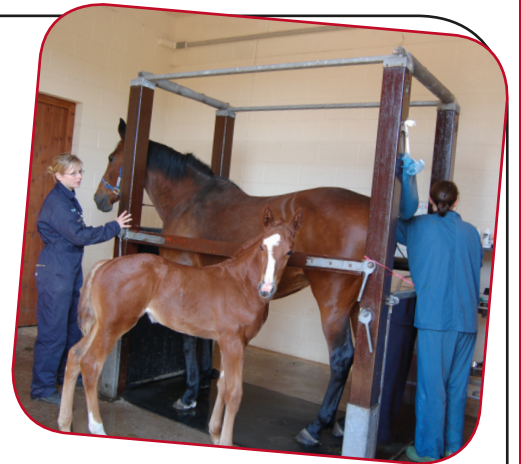

Reproductive Ultrasound

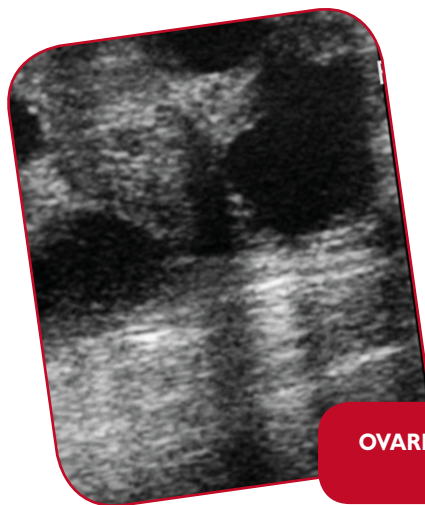Ultrasound imaging has been commonly used to assist with equine reproduction for over thirty years. Advances in technology and image quality have meant that high quality, portable imaging is affordable to most veterinary practices.

Ultrasound is relatively non-invasive and can be performed in many horses without sedation especially where stocks are available to provide restraint. It is most commonly used for assessing the reproductive tract prior to breeding or in mares with behavioural problems and for the detection and monitoring of the progress of pregnancy.



The facts about ultrasound

- The probe used emits ultrasound waves to a depth of up to 12cm. These are reflected back from the tissues to the probe allowing the computer to create an image in different shades of grey.
- The different shades of grey result from the tissues reflecting ultrasound waves back at different intensities; gas and fluid appear black, while soft tissues appear as shades of grey and bone as white. This allows us to differentiate between structures; so an ovary will look different to a uterus and a uterus will look different depending on whether or not the mare is pregnant.
- Ultrasound is non-painful, but due to the size of the equine abdomen it is normal to perform the examination per-rectum. Most horses tolerate this procedure very well. For the safety of the horse and personnel sedation may be used and is in most situations safe, even in pregnant mares.
- Mares are also scanned externally through the body wall, as with human pregnancies. This is normally carried out in the latter stages of pregnancy when the uterus and foetus sit low in the abdomen.



**OVARIAN SCAN SHOWING
FOLLICLES**

KEY POINTS REPRODUCTIVE ULTRASOUND:

- is normally used to assess a mare's suitability for breeding and to predict the most suitable time for covering or artificial insemination (AI);
- is used to detect pregnancy from 14 days and allows the diagnosis and treatment of twin pregnancies;
- can be used to investigate infertility in mares failing to conceive or to maintain a pregnancy;
- trans-abdominal ultrasound can be used to assess foetal health in the latter stages of pregnancy;
- can be used in the investigation of mares with erratic behaviour and suspected hormonal problems.

Reproductive ultrasound examination

Ultrasound is used to assess mares prior to breeding, including examination of the uterus and both ovaries.

The uterus is assessed to determine lining thickness, the presence of any free fluid, along with the presence of any cysts within the lining which may interfere with a pregnancy, or may be mistaken for one on future scans.

Ovaries are examined for the presence of follicles (the egg producing structures) which appear as black spheres on the scan.

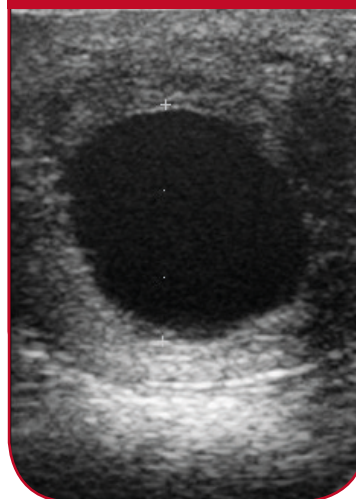
Assessing the stage of the cycle

From looking at both ovaries and the uterus it is possible to determine the approximate stage of the mare's cycle. This allows us to recommend when you should take the mare to the stallion for natural cover and is especially important for AI where timing of insemination is crucial.

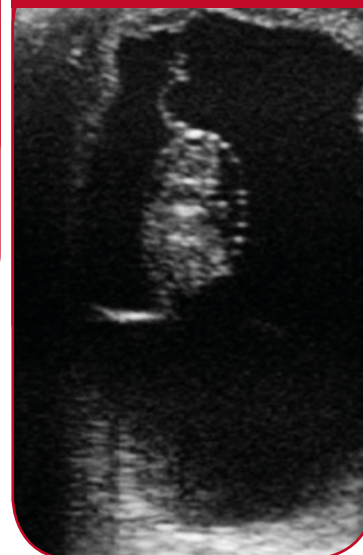Ovarian abnormalities

Ovaries vary markedly in appearance, both in size and structure at different times of year. This is especially important to remember when investigating mares with suspected hormonal problems. Often there are no obvious ultrasonographic changes. However, occasionally the presence of an ovarian tumour called a Granulosa Cell Tumour is detected, causing aggressive or stallion like behaviour.

17 DAY PREGNANCY



35 DAY PREGNANCY



PREGNANCY DIAGNOSIS

Since the uterus is scanned directly through the rectum, pregnancy can be detected as early as about 14 days and in some cases earlier. At this stage the pregnancy appears as a small black sphere in one of the uterine horns. It is important to ensure that only a single pregnancy is present, as mares can't normally safely carry twins to term. If a mare is known to have released two eggs, they should be closely examined for the presence of twins.

As the pregnancy develops, fluid accumulates within the uterus and by day 24 the foetus can be seen as a small bundle of cells, within which its beating heart can be seen.

As pregnancy progresses, both trans-rectal and trans-abdominal ultrasound allow the identification of more developed foetal structures, including foetal sexing.



XLEquine is a novel and exciting initiative conceived from within the veterinary profession made up of independently owned, progressive veterinary practices located throughout the United Kingdom, members of XLEquine are committed to working together for the benefit of all their clients.
© XLVet UK Ltd.

No part of this publication may be reproduced without prior permission of the publisher.

For further information contact your local XLEquine practice:

www.xlequine.co.uk

Go to www.xlequine.co.uk