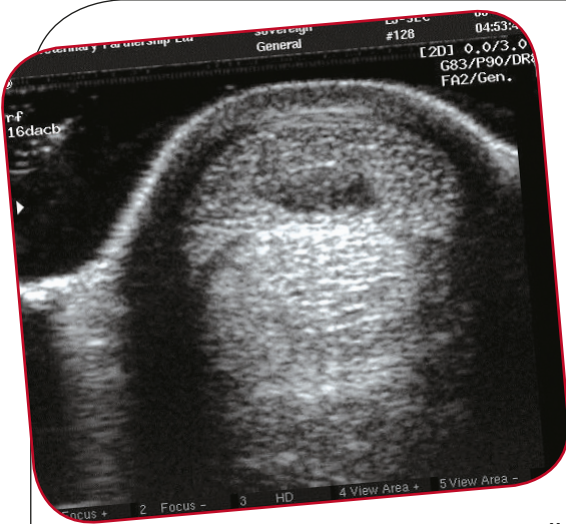

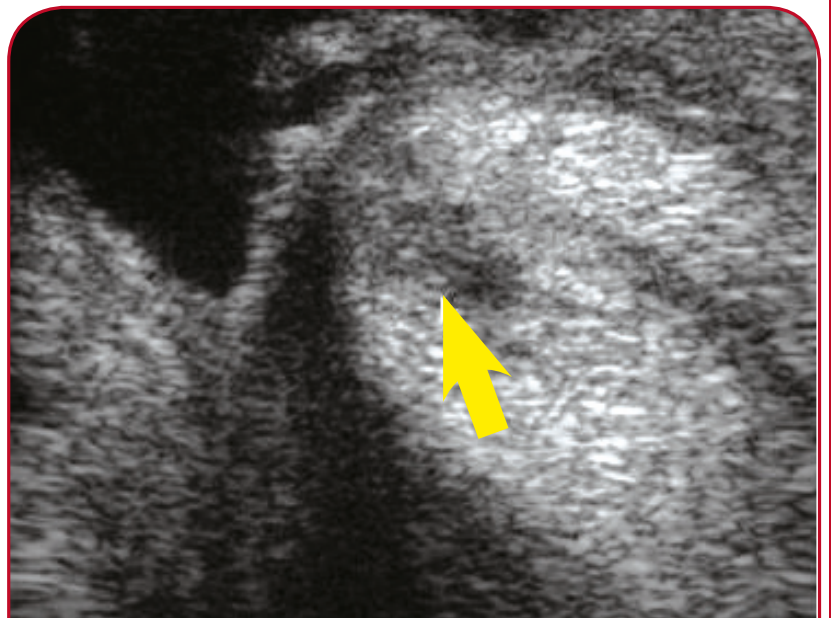


## Orthopaedic Ultrasound Imaging

Ultrasound imaging has been used in equine veterinary practice since the mid 1980s. The original equipment was primarily used to examine the tendons and ligaments along the back of the cannon bone, a common site of injury. With the development of more advanced equipment and the advances in imaging, aided by the digital technology revolution, ultrasound equipment became affordable to most veterinary practices. In recent years, the range of orthopaedic applications of ultrasound has expanded as new techniques are developed and injured tissues are examined in ever increasing detail.

### The facts about ultrasound

- Ultrasound waves emitted from a probe applied to the skin penetrate soft tissues and are reflected back to the probe creating an image.
- Differences between adjacent tissues and between normal and injured tissues result in alterations in the beam returning to the probe.
- Ultrasound waves pass through soft tissues and liquids, but not air or bone. Only the surfaces of bones or joints or air-filled structures can be examined using ultrasound.
- Orthopaedic investigations frequently make use of both ultrasonography and radiography (x-rays), technologies which complement each other well when looking at injuries to the structures of the equine limb.
- Whilst ultrasound imaging is not painful, patients need to stand still during the examination. Light sedation, or the use of stocks, may be necessary to allow preparation of the area and careful scanning.
- Normally, the hair is clipped and the skin cleaned and degreased prior to water based gel being applied to the area of interest, ensuring a good quality image.



**ULTRASOUND HELPED TO DIAGNOSE A TENDON TEAR INSIDE THE FETLOCK TENDON SHEATH, PRIOR TO SURGICAL REPAIR**

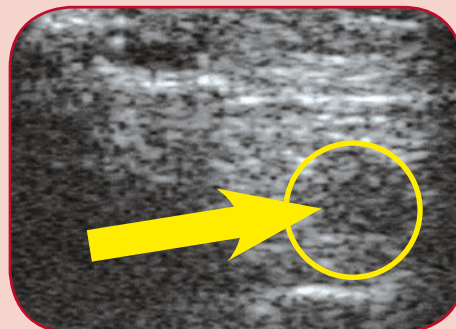
### DIAGNOSTIC ULTRASOUND IMAGING:

- is a non-painful, non-invasive means of examining soft tissues;
- is commonly used to assess tendon and ligament injuries;
- is useful at monitoring healing of soft tissues;
- can also be used to look at the surface of damaged bones and joints;
- is used to accurately guide needles into specific areas during treatment of injuries.

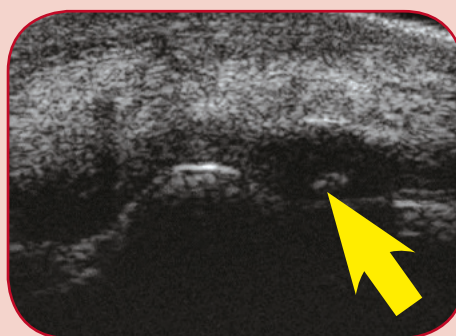
- The most common application of ultrasound is assessing tendon and ligament injuries behind the cannon bone, including the two flexor tendons and the check and suspensory ligaments.
- Ultrasound can also be used to accurately guide needles into the site of injection of an area during treatment. Stem cell therapy employs this technique, where the cells are injected, under ultrasound guidance, into the damaged area of tendon or ligament.
- Following treatment, the healing process can be monitored ultrasonographically to allow an appropriate level of exercise to be undertaken and to gauge when the patient can return to normal work.
- Injuries to tendons and other soft tissues inside tendon canals, such as the one behind the fetlock joint, can also be assessed and treated with the aid of ultrasound imaging.
- Ultrasound can be used to examine localised swellings such as an abscess, or wounds, to look for foreign bodies such as wood, which do not show up on x-ray.
- Joints are traditionally examined using x-rays. Over recent years ultrasound has proven increasingly useful in examining the many ligaments and tendons around joints and also the cartilage surface within the joint.
- New applications and improved methods continue to extend the use of ultrasound in the investigation and treatment of orthopaedic injuries.

### ORTHOPAEDIC ULTRASOUND IMAGES

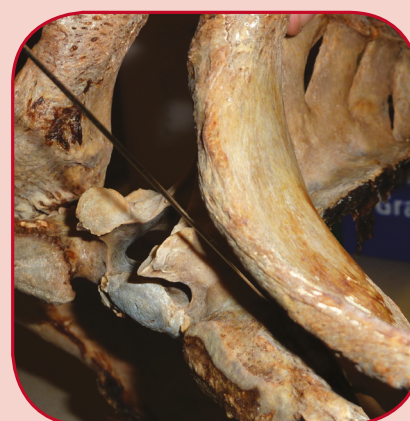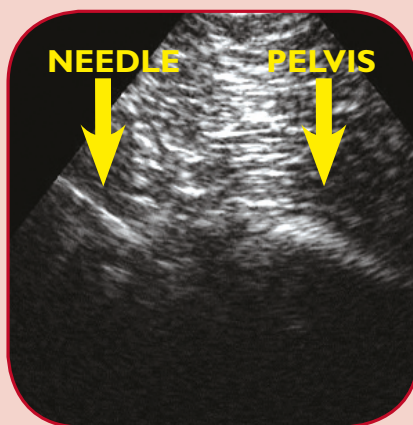
**A torn suspensory ligament just behind the hock area.  
No external swelling was visible.**



**This fetlock joint chip fracture could be measured and its exact location determined by ultrasound prior to surgical removal.**



**Injection of the sacro-iliac joint with anti-inflammatories  
(between the lower back and underside of the pelvis)  
can be carried out using ultrasound guidance.**



XLEquine is a novel and exciting initiative conceived from within the veterinary profession made up of independently owned, progressive veterinary practices located throughout the United Kingdom, members of XLEquine are committed to working together for the benefit of all their clients.  
© XLVet UK Ltd.

No part of this publication may be reproduced without prior permission of the publisher.

For further information contact your local XLEquine practice:

[www.xlequine.co.uk](http://www.xlequine.co.uk)

Go to [www.xlequine.co.uk](http://www.xlequine.co.uk)